






Detection and localisation of primary prostate cancer using ⁶⁸Ga gallium prostate-specific membrane antigen positron emission tomography/computed tomography compared with multiparametric magnetic resonance imaging and radical prostatectomy specimen pathology

Arveen A. Kalapara^{*,†} , Tatenda Nzenza[‡] , Henry Y.C. Pan^{*}, Zita Ballok^{§,¶}, Shaker Ramdave[¶], Richard O'Sullivan^{§,*,**}, Andrew Ryan^{††}, Martin Cherk^{‡‡}, Michael S. Hofman^{§§} , Badrinath R. Konety^{¶¶}, Nathan Lawrentschuk[‡] , Damien Bolton^{***}, Declan G. Murphy^{‡,†††} , Jeremy P. Grummet^{*,†††} and Mark Frydenberg^{*,†}

^{*}Department of Surgery, Monash University, Melbourne, [†]Australian Urology Associates, Malvern, [‡]Division of Cancer Surgery, Peter MacCallum Cancer Centre, Melbourne, [§]Healthcare Imaging Services, Richmond, [¶]Department of Nuclear Medicine and PET, Monash Medical Centre, Bentleigh East, ^{**}Department of Medicine, Monash University, Melbourne, ^{††}TissuPath, Mount Waverley, ^{‡‡}Department of Nuclear Medicine and PET, Alfred Hospital, ^{§§}Centre for Molecular Imaging, Peter MacCallum Cancer Centre, Melbourne, VIC, Australia, ^{¶¶}Department of Urology, University of Minnesota, Minnesota, MN, USA, ^{***}Department of Urology, Austin Hospital, Heidelberg, ^{†††}Sir Peter MacCallum, Department of Oncology, University of Melbourne, Parkville, and ^{††††}Department of Urology, Alfred Hospital, Melbourne, VIC, Australia

Objective

To compare the accuracy of ⁶⁸Ga gallium prostate-specific membrane antigen positron emission tomography/computed tomography (⁶⁸Ga-PSMA PET/CT) with multiparametric MRI (mpMRI) in detecting and localising primary prostate cancer when compared with radical prostatectomy (RP) specimen pathology.

Patients and methods

Retrospective review of men who underwent ⁶⁸Ga-PSMA PET/CT and mpMRI for primary prostate cancer before RP across four centres between 2015 and 2018. Patients undergoing imaging for recurrent disease or before non-surgical treatment were excluded. We defined pathological index tumour as the lesion with highest International Society of Urological Pathology Grade Group (GG) on RP specimen pathology. Our primary outcomes were rates of accurate detection and localisation of RP specimen pathology index tumour using ⁶⁸Ga-PSMA PET/CT or mpMRI. We defined tumour detection as imaging lesion corresponding with RP specimen tumour on any imaging plane, and localisation as imaging lesion matching RP

specimen index tumour in all sagittal, axial, and coronal planes. Secondary outcomes included localisation of clinically significant and transition zone (TZ) index tumours. We defined clinically significant disease as GG 3–5. We used descriptive statistics and the Mann–Whitney *U*-test to define and compare demographic and pathological characteristics between detected, missed and localised tumours using either imaging modality. We used the McNemar test to compare detection and localisation rates using ⁶⁸Ga-PSMA PET/CT and mpMRI.

Results

In all, 205 men were included in our analysis, including 133 with clinically significant disease. There was no significant difference between ⁶⁸Ga-PSMA PET/CT and mpMRI in the detection of any tumour (94% vs 95%, *P* > 0.9). There was also no significant difference between localisation of all index tumours (91% vs 89%, *P* = 0.47), clinically significant index tumours (96% vs 91%, *P* = 0.15) or TZ tumours (85% vs 80%, *P* > 0.9) using ⁶⁸Ga-PSMA PET/CT and mpMRI. Limitations include retrospective

study design and non-central review of imaging and pathology.

Conclusion

We found no significant difference in the detection or localisation of primary prostate cancer between ^{68}Ga -PSMA PET/CT and mpMRI. Further prospective studies are

required to evaluate a combined PET/MRI model in minimising tumours missed by either modality.

Keywords

Prostate cancer, multiparametric MRI, prostate-specific membrane antigen, positron emission tomography, staging, metastases

Introduction

Recent years have seen a significant shift in the diagnostic landscape of localised prostate cancer. Multiparametric MRI (mpMRI) is now a well-established tool in the assessment of primary tumours and has shown high sensitivity and excellent negative predictive values for clinically significant disease [1], leading to increasing uptake of pre-biopsy mpMRI and targeted prostate biopsy [2–4]. Contemporary diagnostic biopsy, therefore, relies on precise identification of index tumour location on imaging. An index tumour is conventionally regarded as the focus of intra-prostatic cancer with the highest grade and carries important clinical implications from a prognostic standpoint [5]. Moreover, knowing index tumour location adds value to diagnostic and therapeutic approaches, including targeted biopsy and treatment. Despite its accuracy, some concerns remain around underestimation of tumour size and identification of transition zone (TZ) lesions using mpMRI [6,7].

^{68}Ga -labelled prostate-specific membrane antigen positron emission tomography (^{68}Ga -PSMA PET) has emerged as a viable staging tool alongside mpMRI [8,9]. PSMA is a transmembrane protein found on prostatic cells and overexpressed in prostate cancer [10], and targeting this using ^{68}Ga -PSMA PET/CT has shown promise in accurately re-staging recurrent disease [11,12] and improving detection of lymph node metastases when compared with mpMRI [13–15]. Still, beyond evidence for its utility in advanced disease, the added potential of PSMA PET/CT in detecting and characterising primary prostate cancer lesions remains to be fully explored [16,17], along with any clinical benefit it offers over mpMRI. We aimed to assess the accuracy of ^{68}Ga -PSMA PET/CT compared with mpMRI in detecting and localising primary prostate cancer lesions when compared with radical prostatectomy (RP) specimen pathology.

Patients and methods

We performed a retrospective review of men who underwent ^{68}Ga -PSMA PET/CT and mpMRI for primary prostate cancer before RP across four Australian centres between 2015 and 2018. Patients undergoing re-staging for recurrent disease or

non-surgical treatment, including any focal therapy, were excluded. Ethical approval was obtained from the Monash University and University of Melbourne (Melbourne, VIC, Australia). Clinical and demographic characteristics were collected, including age and PSA level at diagnosis. PSA density (PSAD) was calculated using prostate volume on mpMRI.

Patients underwent ^{68}Ga -PSMA PET/CT across four Australian institutions. PET/CT imaging was performed on Siemens Biograph mCT Excel, Siemens Biograph mCT Flow (Siemens Healthineers, Erlangen, Germany) and GE 710 Discovery (GE Healthcare, Chicago, IL, USA) PET/CT scanners. Imaging was reviewed and reported by nuclear medicine physicians (Z.B., S.R., M.C., M.S.H.). The index lesion on ^{68}Ga -PSMA PET/CT was defined as the focal lesion with the highest avidity, quantified by maximum standardised uptake value (SUV_{max}), regardless of size. As such, when a small lesion with greater avidity and large lesion with lesser avidity were present, the smaller focus was considered the index lesion. All other lesions found on imaging were considered non-index. Scans with no focal lesion and mild diffuse uptake only, were considered negative.

^{68}Ga -PSMA PET/CT scanning protocols were similar across sites. Our first site used a Siemens Biograph mCT PET/CT scanner to acquire PET images from thighs to vertex at 60 min after administration of 2 MBq/kg body weight $\pm 5\%$ of ^{68}Ga -PSMA. Our second site used a Siemens Biograph mCT 20 with extended field of view (FOV) Biograph PET/CT scanner to acquire PET images from thighs to vertex at 45–60 min after administration of 2 MBq/kg body weight $\pm 5\%$ up to 300 MBq of ^{68}Ga -PSMA. Our third site used a GE 710 Discovery PET/CT scanner to acquire PET images from the pelvis towards the head at 45–75 min after administration of 1.8–2.2 MBq/kg body weight of ^{68}Ga -PSMA-11. Finally, our fourth site also used a GE 710 Discovery PET/CT scanner to acquire PET images from thighs to vertex at 55–60 min after administration of 2 MBq/kg body weight $\pm 5\%$ up to 200 MBq of ^{68}Ga -PSMA. At all sites, a low-dose non-contrast CT was performed during tidal respiration for attenuation correction and anatomical correlation.

All mpMRI images included were acquired using 3-T MRI scanners, and imaging was reviewed and reported by specialised MRI radiologists, as per Prostate Imaging-Reporting and Data System (PI-RADS), version 2 [18]. The index lesion on mpMRI was defined as that with the highest PI-RADS score. In the case of multiple lesions, those with lower PI-RADS scores were considered non-index. If two lesions with identical PI-RADS score were identified on MRI, the larger lesion was deemed the index tumour.

Findings on ⁶⁸Ga-PSMA PET/CT and mpMRI were compared with histopathology on formalin-fixed and paraffin-embedded RP specimens, as reported by specialised uro-pathologists. The index tumour on RP specimen pathology was defined as the lesion with highest International Society of Urological Pathology (ISUP) Grade Group (GG). In men with multiple foci with identical tumour grade, again, the larger lesion was deemed the index tumour.

Our primary outcomes included rates of accurate detection and localisation of index tumour found on RP specimen pathology, using ⁶⁸Ga-PSMA PET/CT or mpMRI. Detection of cancer was defined as identification of any corresponding lesion between imaging and histopathology, both index and non-index, in any imaging plane. Tumour localisation was considered accurate if the location of the index tumour on imaging correlated with that of the index tumour on the RP specimen in all three planes: sagittal (left, right), axial (apex, mid, base), and coronal (anterior, posterior). Index lesions on imaging, which met all three criteria, but only partially overlapped with the pathological lesion were also considered accurate, as imaging-targeted biopsy of these lesions would still sample the histological index tumour. Clinically significant disease was defined as ISUP GG 3–5. Secondary outcomes included the localisation of clinically significant index tumours and localisation of index tumours in the TZ/ anterior and peripheral prostatic zones.

Statistical analysis

Descriptive statistics were used for demographic and pathological characteristics of the overall cohort. The Mann-Whitney *U*-test was used to compare demographic and pathological characteristics of tumours detected, missed and localised using either imaging modality. The McNemar test was used to compare detection and localisation accuracy of PET/CT and mpMRI within the cohort. All statistical analyses were performed using the Statistical Package for the Social Sciences (SPSS®), version 25 (SPSS Inc., IBM Corp., Armonk, NY, USA).

Results

In all, 205 men who underwent both ⁶⁸Ga-PSMA PET/CT and mpMRI before RP were included in our analysis. Cohort

characteristics are listed in Table 1. The median age was 67 years and patients had a median PSA level of 7.18 ng/mL before imaging. The median PSAD was 0.204 ng/mL/mL. All men had prostate cancer on final histopathology, including 133 (64.9%) with clinically significant disease (GG 3–5) and 127 (62.0%) with non-organ confined disease (Table 1). All 205 men had a GG ≥2 index tumour on final pathology.

Detection of any prostate cancer

In all, 193 (94.1%) of 205 ⁶⁸Ga-PSMA PET/CT scans showed a focal lesion with PSMA avidity corresponding with any tumour on RP specimen pathology, and similarly a focal lesion was found in 194 (94.6%) MRI scans. There was no significant difference between the modalities for detection of any tumour ($P > 0.9$). Examples of the tumours detected and missed on ⁶⁸Ga-PSMA PET/CT and mpMRI are shown in Fig. 1.

In total, 127 (62.0%) of the men had non-organ confined tumours, including 86 with pT3a and 41 with pT3b tumours. Of the 127 men with pT3 disease, ⁶⁸Ga-PSMA PET/CT detected 120 (94.5%) index tumours, whilst mpMRI detected 123 (96.9%) ($P = 0.549$). Similarly, ⁶⁸Ga-PSMA PET/CT localised 118 (92.9%) of these tumours, which was not significantly less than the 120 (94.5%) by mpMRI ($P = 0.791$).

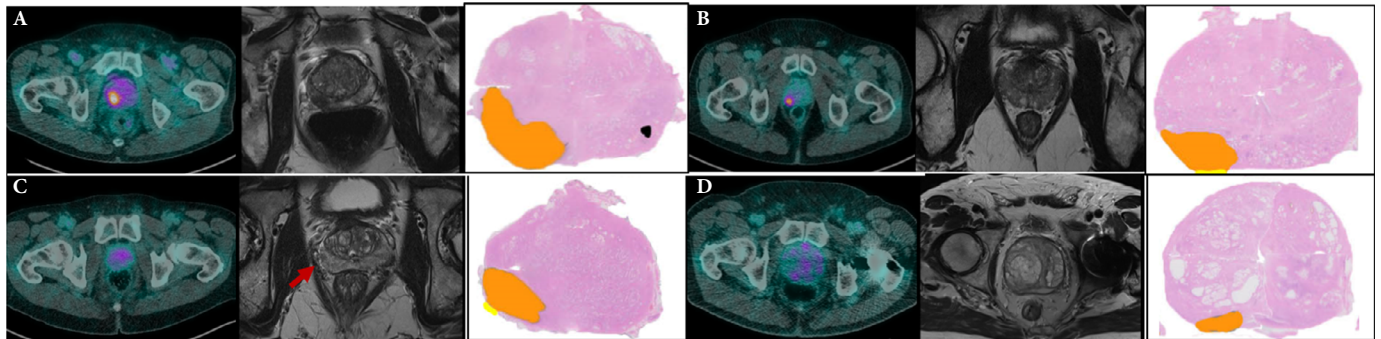
Missed index tumours

Clinical and pathological characteristics of the men with index tumours missed on ⁶⁸Ga-PSMA PET/CT or mpMRI are

Table 1 Demographic and pathological features of the cohort ($n = 205$).

Variable	Value
Demographics	
Age, years, median (IQR)	67 (61–72)
PSA level, ng/mL, median (IQR)	7.18 (4.90–10.20)
PSAD, ng/mL/mL, median (IQR)	0.204 (0.145–0.305)
Features on mpMRI	
PI-RADS score, n (%)	
2	10 (4.9)
3	14 (6.8)
4	93 (45.4)
5	88 (42.9)
Pathological features of RP specimen	
Index tumour ISUP GG, n (%)	
GG 2	72 (35.1)
GG 3	87 (42.4)
GG 4	10 (4.9)
GG 5	36 (17.6)
Pathological T-stage, n (%)	
pT2	78 (38.0)
pT3a	86 (42.0)
pT3b	41 (20.0)
Index tumour volume, mL, median (IQR)	2.8 (1.5–5.8)
Index tumour zonal location, n (%)	
Peripheral zone only	145 (70.7)
TZ only	20 (9.8)
Both	40 (19.5)

Fig. 1 Tumours detected and missed on mpMRI and ^{68}Ga -PSMA PET/CT with RP specimen histological comparison. (A) PET/CT and mpMRI both positive; (B) PET/CT positive and mpMRI negative; (C) PET/CT negative and mpMRI positive; (D) PET/CT and mpMRI both negative.



listed in Table 2. In all, 12 (5.9%) index tumours on RP specimen pathology were non-avid on ^{68}Ga -PSMA PET/CT, including 10 with no PSMA avidity and two men had PSMA uptake that did not correspond with any focus of tumour on histopathology (Fig. 2). These men had a median (interquartile range [IQR]) PSA level of 5.25 (3.63–8.43) ng/mL. The median (IQR) PSAD was 0.114 (0.075–0.143) ng/mL/mL, lower than the 0.213 (0.155–0.311) ng/mL/mL for tumours detected on PET/CT ($P < 0.001$). Correspondingly, patients with non-PSMA PET avid lesions had a lower median (IQR) index tumour volume on RP specimen pathology of 1.4 (0.8–2.2) mL, compared with 3.0 (1.6–6.0) mL for PSMA PET avid lesions ($P = 0.002$). Three of these 10 tumours were clinically significant, one each being GG 3, 4 and 5. The

remaining seven tumours were GG 2. Notably, seven of 12 men had pT3a tumours.

In all, 11 (5.4%) index tumours were not detected on mpMRI, including 10 showing no focal lesion on imaging and one with a focal lesion that did not correspond with any intra-prostatic tumour. These men had a median (IQR) PSA level of 9.90 (4.94–18.60) ng/mL. The median (IQR) PSAD was 0.260 (0.159–0.380) ng/mL/mL, not significantly different from 0.200 (0.144–0.297) ng/mL/mL for those lesions seen on mpMRI ($P = 0.254$). However, the median (IQR) index tumour volume on RP specimen pathology was 1.2 (0.6–2.8) mL, significantly lower than 2.9 (1.6–6.0) mL for mpMRI visible lesions ($P = 0.003$). These 11 missed tumours consisted of six GG 2, four GG 3, and one GG 5 lesion. Four men had non-organ confined disease, including three men with pT3a and one man with pT3b tumours.

Table 2 Clinical and tumour characteristics in men with non-avid ^{68}Ga -PSMA PET/CT or non-visible lesions on mpMRI.

Variable	^{68}Ga -PSMA PET/CT	mpMRI
N	12	11
Age, years, median (IQR)	71 (65–69)	65 (63–69)
PSA level, ng/mL, median (IQR)	5.25 (3.63–8.43)	9.90 (4.94–18.60)
PSAD, ng/mL/mL, median (IQR)	0.114 (0.075–0.143)	0.260 (0.159–0.380)
Pathological features of RP specimen		
Index tumour volume, mL, median (IQR)	1.4 (0.8–2.2)	1.2 (0.6–2.8)
ISUP GG, n/N		
2	9/12	6/11
3	1/12	4/11
4	1/12	0/11
5	1/12	1/11
pT-stage, n/N		
pT3	7/12	4/11
Index tumour zonal location, n/N		
Peripheral zone only	10/12	8/11
TZ only	2/12	2/11
Both	0/12	1/11
Index tumour location (left/right), n/N		
Right-sided only	6/12	5/11
Left-sided only	4/12	3/11
Bilateral	2/12	3/11

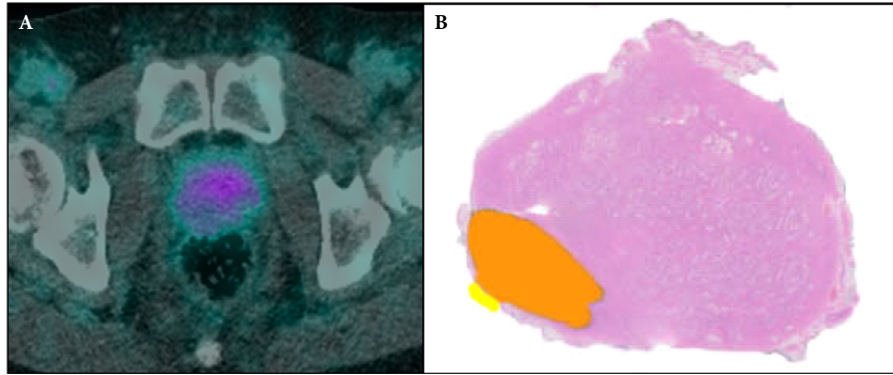
Only one (0.5%) index lesion on RP specimen pathology was missed on both ^{68}Ga -PSMA PET/CT and mpMRI. This patient had GG 2 disease on RP specimen pathology with a very small index tumour volume of 0.4 mL. mpMRI identified 11 of the 12 lesions missed by ^{68}Ga -PSMA PET/CT, and PET/CT identified 10 of the 11 tumours missed on MRI.

Index tumour localisation

^{68}Ga -PSMA PET/CT accurately localised the index tumour on RP specimen pathology in 176 (85.9%) of 205 men. In a further 11 men (5.4%), the index tumour on RP specimen pathology corresponded with non-index lesions with lower SUV_{max} values on ^{68}Ga -PSMA PET/CT. When adding these lesions, ^{68}Ga -PSMA PET/CT was able to accurately localise 187 (91.2%) index tumours identified on RP specimen pathology.

mpMRI accurately localised the index tumour in 180 (87.8%) of 205 men. In a further two men (1.0%), the index tumour

Fig. 2 Example of non-avid lesion on ⁶⁸Ga-PSMA PET/CT (A) compared with whole mount histopathology (B). A 60-year-old man, PSA level 3.2 ng/mL, with no focal lesion on ⁶⁸Ga-PSMA PET/CT. Final pathology on RP specimen was ISUP GG 2, stage pT3a.



on RP specimen pathology corresponded with non-index lesion location found on MRI with a lower PI-RADS score, giving a cumulative localisation rate of 88.8% using mpMRI. There was no significant difference between overall localisation of index tumours using ⁶⁸Ga-PSMA PET/CT (91.2%) and mpMRI (88.8%) ($P = 0.472$). Localisation by RP segments in the sagittal and coronal planes are shown in Table 3.

In all, 133 (64.9%) of 205 index tumours were clinically significant, with an ISUP GG of 3–5. In all, 127 (95.5%) of these clinically significant index tumours were localised by ⁶⁸Ga-PSMA PET/CT, and 121 (91.0%) were found on mpMRI ($P = 0.146$). Three clinically significant index tumours were not completely localised on both imaging modalities, but all were detected by either ⁶⁸Ga-PSMA PET/CT or mpMRI. Localisation of index tumours stratified by ISUP GG is shown in Fig. 3. There was no significant difference between ⁶⁸Ga-PSMA PET/CT and mpMRI in the localisation of GG 2 (83% vs 85%, $P > 0.9$), GG 3 (97% vs 92%, $P = 0.29$), GG 4 (90% vs 80%, $P > 0.9$) or GG 5 (94% vs 92%, $P > 0.9$) tumours.

In all, 20 tumours were found exclusively in the TZ or anterior zone on histopathology, of which ⁶⁸Ga-PSMA PET/CT localised 17 (85%) and mpMRI localised 16 (80%) ($P > 0.9$). Similarly, there was no difference in localisation of 145 peripheral zone index tumours between PET/CT (130, 89.7%) and mpMRI (127, 87.6%) ($P = 0.690$).

Discussion

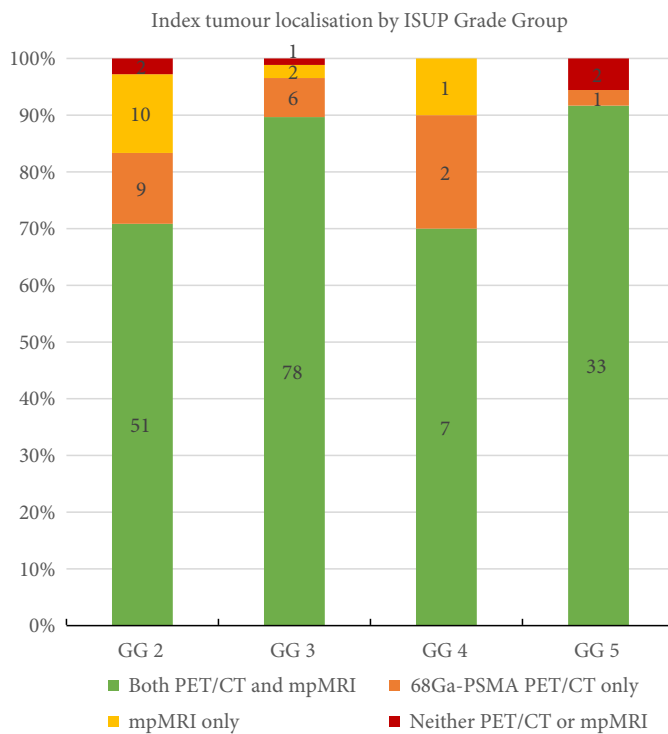
The diagnosis and initial management of localised prostate cancer have grown increasingly reliant on imaging findings following the introduction of mpMRI and, more recently, ⁶⁸Ga-PSMA PET/CT. While mpMRI is now recommended before biopsy in men with a suspicion of localised prostate cancer [19], the emerging role of ⁶⁸Ga-PSMA PET/CT in primary staging is predominantly focussed on staging of regional and distant disease. Little is yet known of the value of ⁶⁸Ga-PSMA PET/CT in primary staging of lesions within the prostate itself. Despite the inherently heterogeneous and multifocal nature of prostate cancer, the highest tumour grade found on pathology remains a strong prognostic indicator for recurrence-free, metastasis-free and cancer-specific survival [5,20,21]. Identification of these lesions on imaging, therefore, is pertinent to decision-making surrounding diagnostic biopsy approach and local treatment options offered to patients. We assessed intra-prostatic index tumour detection and localisation using ⁶⁸Ga-PSMA PET/CT and mpMRI, and found equivalent rates for both. To our knowledge, our present study is the largest in the literature comparing the accuracy of these modalities in localising primary prostate cancer lesions.

Detection

Both ⁶⁸Ga-PSMA PET/CT and mpMRI detected any tumour on RP specimen pathology in 94% of our present cohort, and

Table 3 Sagittal and coronal location of index tumours on RP specimen accurately localised by ⁶⁸Ga-PSMA PET/CT and mpMRI.

Plane	Location	⁶⁸ Ga-PSMA PET/CT, n (%)	mpMRI, n (%)	No. of index tumours on RP specimen
Sagittal	Left only	70 (93.3)	66 (88.0)	75
	Right only	48 (85.7)	46 (82.2)	56
	Bilateral	69 (93.2)	70 (94.6)	74
Coronal	Anterior only	31 (86.1)	31 (86.1)	36
	Posterior only	116 (89.9)	111 (86.0)	129
	Both	40 (100)	40 (100)	40

Fig. 3 Localisation of index tumour by ISUP GG.

96% and 91% of clinically significant index tumours were identified by ^{68}Ga -PSMA PET/CT and mpMRI, respectively. A recent Australian study found similar rates, but reported superior detection using ^{68}Ga -PSMA PET/CT over mpMRI, at 100% and 94%, respectively [22]. Discrepancy from our present results may lie in varying definitions of index tumours; whilst defined as the lesion with highest tumour grade in our present cohort, Berger et al. [22] assessed the detection of the largest tumour found on RP specimen pathology. Larger lesions may be better detected using either modality, and accordingly smaller lesions with higher tumour grade may be more commonly missed. This was confirmed in a large, prospective cohort comparing mpMRI with RP specimen pathology in which tumour size was found to be the strongest predictor of detection on imaging, and missed clinically significant lesions were smaller than those that were visualised [23]. These results corroborate our present finding of significantly smaller index tumour volumes in ^{68}Ga -PSMA PET/CT non-avid and MRI invisible tumours. A randomised multicentre study of 300 patients undergoing PET/CT and conventional imaging has recently completed accrual and will provide prospective data on the performance of ^{68}Ga -PSMA PET/CT in the primary staging setting [24].

Other cohorts have reported sensitivity ranging between 49% and 68%, and specificity between 92% and 95%, for detection of any tumour on ^{68}Ga -PSMA PET/CT [25–27], regardless of index tumour status, demonstrating no significant difference

between mpMRI and ^{68}Ga -PSMA PET/CT [25]. The high sensitivity of ^{68}Ga -PSMA PET/CT suggests it may have a role in reducing uncertainty when excluding high-risk disease before inclusion on active surveillance or reassurance in men with rising PSA despite negative prostate biopsy. Nevertheless, consistent with existing reports suggesting 5% of tumours lack PSMA expression on immunostaining [28], 6% of index tumours in our present cohort were non-avid on ^{68}Ga -PSMA PET/CT, potentially influencing detection rates. Again, these tumours were significantly smaller in volume than those visible on imaging, and one-third were clinically significant.

Localisation

Accurate localisation of clinically significant tumours within the prostate carries wide diagnostic and treatment implications. mpMRI has been proposed as a triaging tool, and sampling of MRI lesion-targeted cores has become paramount in contemporary biopsy practices, replacing systematic cores in some settings [29]. Equivalent localisation using ^{68}Ga -PSMA PET/CT raises the possibility of its use as a primary diagnostic tool in this domain as well. In a North American cohort of MRI-negative or MRI-naïve men with prior negative biopsy, ^{68}Ga -PSMA PET/TRUS fusion-guided biopsy yielded 82% sensitivity and of 72% specificity for any cancer, and 100% sensitivity for clinically significant disease [30]. Although only targeted biopsy cores were sampled in that study, potentially overestimating sensitivity, these results are somewhat promising, particularly for men who are ineligible for mpMRI. PSMA expression is also associated with tumour grade [28], and further investigation of the predictive ability of other parameters on ^{68}Ga -PSMA PET/CT, such as SUV, are required to identify whether PET/CT can function as a stand-alone test in this space.

Accordingly, this raises the potential of ^{68}Ga -PSMA PET/CT as a single test to assess both local and distant disease. ^{68}Ga -PSMA PET/CT has confirmed sensitivity in detecting metastases when compared with nodal histopathology in primary staging [31], and thus may have utility in detecting oligometastatic spread, thereby upstaging tumours that would otherwise be considered localised. Given anterior periprostatic tissue contains lymph nodes in 30% of men [32], detection of disease here using ^{68}Ga -PSMA PET/CT may also guide the adjustment of margins and surgical technique, including pelvic lymph node dissection, accordingly. From a treatment standpoint, confidence in tumour location can also guide decision-making in nuances such as nerve sparing during RP and lesion-specific focal therapy.

Predominantly TZ and anterior zone tumours have been traditionally more difficult to reach on biopsy, particularly from a transrectal approach, and thus need to be effectively localised using pre-biopsy imaging. Existing evidence for MRI

in detecting impalpable anterior tumours missed by TRUS biopsy [33] is compounded by our present finding of equivalent localisation rates using ⁶⁸Ga-PSMA PET/CT, suggesting molecular imaging may have a similar role in identifying these tumours.

Our present finding of no significant difference in index tumour localisation rates between modalities is discrepant with some existing studies demonstrating inferior performance using mpMRI [22]. Almost all mpMRI scans in our present study were performed at a high-volume centre and reported by specialised MRI radiologists with significant experience in prostate mpMRI, perhaps overestimating sensitivity in our present cohort. Conversely, although PSMA avidity allows identification of focal lesions on PET/CT, assessment of true lesion size is difficult due to lack of sufficient detail on the CT component, and as apparent lesion size is dependent on the SUV threshold used at the time of reporting, which can be variable. The degree of anatomical detail offered by imaging is an important consideration in planning for focal therapy. Underestimation of tumour size on mpMRI remains a concern [6,34], and ⁶⁸Ga-PSMA PET/CT may suffer from a similar drawback, with attempts to estimate tumour volume using SUV thresholds to contour lesion borders revealing only moderate histopathological correlation [25]. Consequently, a combination of mpMRI at the voxel level, co-registered with PSMA PET, is being explored as a machine learning framework to optimise planning for focal therapy [35].

Our present study has a number of limitations. Firstly, as a result of its retrospective nature, radiologists and nuclear medicine physicians were not blinded to either mpMRI or ⁶⁸Ga-PSMA PET/CT results when reporting scans. Any cross-examination of scans may have potentially overestimated the sensitivity of either test. Secondly, although required to precisely assess tumour location, evaluation of these imaging techniques in a RP cohort introduces selection bias, potentially overestimating imaging accuracy in a group of men with higher-grade tumours. Men referred to undergo ⁶⁸Ga-PSMA PET/CT are inherently likely to be of intermediate–high clinical risk, compounding this potential bias. Our present study was also limited to the characterisation of index tumours. Although we selected this outcome based on its prognostic significance, this meant only sensitivity and not specificity could be assessed. Finally, as mentioned earlier, more discrete evaluation of tumour volume and extent was not feasible on PET/CT, limiting classification of lesion location to sextant areas. Both of these issues may be addressed in future by way of large, per-segment or voxel-wise analyses [35].

It is possible that, ultimately, a combined ⁶⁸Ga-PSMA PET/MRI approach may be the ideal tool in characterising primary disease on imaging. PSMA PET adds high sensitivity

and staging accuracy to the anatomical detail afforded by mpMRI, and early studies have shown promising results in using PET/MRI to improve the localisation of tumours when compared with either modality alone [16]. However, PET/MRI is an expensive platform and is predominantly restricted to the research setting. Fusion of mpMRI and PET/CT acquired independently may be a more practical approach.

Conclusion

We found no significant difference in the overall detection or localisation of primary prostate cancer between ⁶⁸Ga-PSMA PET/CT and mpMRI. Both modalities were also comparable in the detection of clinically significant cancer and TZ tumours. Tumours that were missed using either ⁶⁸Ga-PSMA PET/CT or mpMRI were smaller and associated with a lower PSAD. Further studies are required to compare the localisation accuracy of ⁶⁸Ga-PSMA PET/CT and mpMRI per-segment, and also evaluate the added utility of a combined PET/MRI model.

Conflict of Interest

MSH is supported by a Clinical Fellowship Award from the Peter MacCallum Foundation. He research is also support by grants from Movember, Prostate Cancer Foundation (PCF), Prostate Cancer Foundation of Australia (PCFA) and the United States Department of Defence.

References

- 1 Ahmed HU, El-Shater Bosaily A, Brown LC et al. Diagnostic accuracy of multi-parametric MRI and TRUS biopsy in prostate cancer (PROMIS): a paired validating confirmatory study. *Lancet* 2017; 389: 815–22
- 2 Nzenza T, Murphy DG. PRECISION delivers on the PROMIS of mpMRI in early detection. *Nat Rev Urol* 2018; 15: 529–30
- 3 Hansen NL, Barrett T, Kesch C et al. Multicentre evaluation of magnetic resonance imaging supported transperineal prostate biopsy in biopsy-naïve men with suspicion of prostate cancer. *BJU Int* 2018; 122: 40–9
- 4 Barnett CL, Davenport MS, Montgomery JS, Wei JT, Montie JE, Denton BT. Cost-effectiveness of magnetic resonance imaging and targeted fusion biopsy for early detection of prostate cancer. *BJU Int* 2018; 122: 50–8
- 5 Epstein JI, Zelefsky MJ, Sjoberg DD et al. A contemporary prostate cancer grading system: a validated alternative to the Gleason score. *Eur Urol* 2016; 69: 428–35
- 6 Priester A, Natarajan S, Khoshnoodi P et al. Magnetic resonance imaging underestimation of prostate cancer geometry: use of patient specific molds to correlate images with whole mount pathology. *J Urol* 2017; 197: 320–6
- 7 Hoeks CM, Hambroek T, Yakar D et al. Transition zone prostate cancer: detection and localization with 3-T multiparametric MR imaging. *Radiology* 2013; 266: 207–17
- 8 Murphy DG, Azad AA, Sandhu S, Violet J, Hofman MS. Prostate-specific membrane antigen across the spectrum of prostate cancer: detection, surgery, and theranostics. *Eur Urol* 2019; 75: 927–8
- 9 Murphy DG, Hofman M, Lawrentschuk N, Maurer T. Bringing clarity or confusion? The role of prostate-specific membrane antigen positron-emission/computed tomography for primary staging in prostate cancer. *BJU Int* 2017; 119: 194–5

- 10 Maurer T, Eiber M, Schwaiger M, Gschwend JE. Current use of PSMA-PET in prostate cancer management. *Nat Rev Urol* 2016; 13: 226–35
- 11 Perera M, Papa N, Roberts M et al. Gallium-68 prostate-specific membrane antigen positron emission tomography in advanced prostate cancer—updated diagnostic utility, sensitivity, specificity, and distribution of prostate-specific membrane antigen-avid lesions: a systematic review and meta-analysis. *Eur Urol* 2020; 77: 403–17
- 12 van Leeuwen PJ, Stricker P, Hruby G et al. (68) Ga-PSMA has a high detection rate of prostate cancer recurrence outside the prostatic fossa in patients being considered for salvage radiation treatment. *BJU Int* 2016; 117: 732–9
- 13 Chaloupka M, Herlemann A, D’Anastasi M et al. ⁶⁸Gallium-prostate-specific membrane antigen PET/computed tomography for primary and secondary staging in prostate cancer. *Urol Clin North Am* 2017; 44: 557–63
- 14 van Leeuwen PJ, Emmett L, Ho B et al. Prospective evaluation of ⁶⁸Gallium-prostate-specific membrane antigen positron emission tomography/computed tomography for preoperative lymph node staging in prostate cancer. *BJU Int* 2017; 119: 209–15
- 15 van Leeuwen PJ, Donswijk M, Nandurkar R et al. Gallium-68-prostate-specific membrane antigen (⁶⁸Ga-PSMA) positron emission tomography (PET)/computed tomography (CT) predicts complete biochemical response from radical prostatectomy and lymph node dissection in intermediate- and high-risk prostate cancer. *BJU Int* 2019; 124: 62–8
- 16 Eiber M, Weirich G, Holzapfel K et al. Simultaneous ⁶⁸Ga-PSMA HBED-CC PET/MRI improves the localization of primary prostate cancer. *Eur Urol* 2016; 70: 829–36
- 17 Hofman MS, Eu P, Jackson P et al. Cold kit for prostate-specific membrane antigen (PSMA) PET imaging: phase 1 study of ⁶⁸Ga-Tris (Hydroxypyridinone)-PSMA PET/CT in patients with prostate cancer. *J Nucl Med* 2018; 59: 625–31
- 18 Weinreb JC, Barentsz JO, Choyke PL et al. PI-RADS prostate imaging—reporting and data system: 2015, Version 2. *Eur Urol* 2016; 69: 16–40
- 19 Mottet N, van den Bergh RC, Briers E et al. EAU – ESTRO – ESUR – SIOG guidelines on Prostate Cancer. *EAU Guidelines* 2018. Available at: <http://www.egu.europa.eu/guidelines>
- 20 Leapman MS, Cowan JE, Simko J et al. Application of a prognostic Gleason grade grouping system to assess distant prostate cancer outcomes. *Eur Urol* 2017; 71: 750–9
- 21 He J, Albertsen PC, Moore D, Rotter D, Demissie K, Lu-Yao G. Validation of a contemporary five-tiered Gleason grade grouping using population-based data. *Eur Urol* 2017; 71: 760–3
- 22 Berger I, Annabattula C, Lewis J et al. ⁶⁸Ga-PSMA PET/CT vs. mpMRI for locoregional prostate cancer staging: correlation with final histopathology. *Prostate Cancer Prostatic Dis* 2018; 21: 204–11
- 23 Johnson DC, Raman SS, Mirak SA et al. Detection of individual prostate cancer foci via multiparametric magnetic resonance imaging. *Eur Urol* 2019; 75: 712–20
- 24 Hofman MS, Murphy DG, Williams SG et al. A prospective randomized multicentre study of the impact of gallium-68 prostate-specific membrane antigen (PSMA) PET/CT imaging for staging high-risk prostate cancer prior to curative-intent surgery or radiotherapy (proPSMA study): clinical trial protocol. *BJU Int* 2018; 122: 783–93
- 25 Rhee H, Thomas P, Shepherd B et al. Prostate specific membrane antigen positron emission tomography may improve the diagnostic accuracy of multiparametric magnetic resonance imaging in localized prostate cancer. *J Urol* 2016; 196: 1261–7
- 26 Fendler WP, Schmidt DF, Wenter V et al. ⁶⁸Ga-PSMA PET/CT detects the location and extent of primary prostate cancer. *J Nucl Med* 2016; 57: 1720–5
- 27 Koerber SA, Utzinger MT, Kratochwil C et al. ⁶⁸Ga-PSMA-11 PET/CT in newly diagnosed carcinoma of the prostate: correlation of intraprostatic PSMA uptake with several clinical parameters. *J Nucl Med* 2017; 58: 1943–8
- 28 Minner S, Wittmer C, Graefen M et al. High level PSMA expression is associated with early PSA recurrence in surgically treated prostate cancer. *Prostate* 2011; 71: 281–8
- 29 Kasivisvanathan V, Rannikko AS, Borghi M et al. MRI-targeted or standard biopsy for prostate-cancer diagnosis. *N Engl J Med* 2018; 378: 1767–77
- 30 Lopci E, Saita A, Lazzeri M et al. ⁶⁸Ga-PSMA positron emission tomography/computerized tomography for primary diagnosis of prostate cancer in men with contraindications to or negative multiparametric magnetic resonance imaging: a prospective observational study. *J Urol* 2018; 200: 95–103
- 31 Herlemann A, Wenter V, Kretschmer A et al. ⁶⁸Ga-PSMA positron emission tomography/computed tomography provides accurate staging of lymph node regions prior to lymph node dissection in patients with prostate cancer. *Eur Urol* 2016; 70: 553–7
- 32 Finley DS, Deane L, Rodriguez E et al. Anatomic excision of anterior prostatic fat at radical prostatectomy: implications for pathologic upstaging. *Urology* 2007; 70: 1000–3
- 33 Lawrentschuk N, Haider MA, Daljeet N et al. ‘Prostatic evasive anterior tumours’: the role of magnetic resonance imaging. *BJU Int* 2010; 105: 1231–6
- 34 Bratan F, Melodelima C, Souchon R et al. How accurate is multiparametric MR imaging in evaluation of prostate cancer volume? *Radiology* 2015; 275: 144–54
- 35 Reynolds HM, Williams S, Jackson P et al. Voxel-wise correlation of positron emission tomography/computed tomography with multiparametric magnetic resonance imaging and histology of the prostate using a sophisticated registration framework. *BJU Int* 2019; 123: 1020–30

Correspondence: Arveen A. Kalapara, Department of Surgery, Monash University, Melbourne, VIC, Australia.

e-mail: arveenkalapara@gmail.com

Abbreviations: ⁶⁸Ga-PSMA PET/CT, ⁶⁸gallium-prostate-specific membrane antigen positron emission tomography/CT; GG, ISUP Grade Group; IQR, interquartile range; ISUP, International Society of Urological Pathology; mpMRI, multiparametric MRI; PSAD, PI-RADS Prostate Imaging-Reporting and Data System; PSMA, prostate-specific membrane antigen; RP, radical prostatectomy; SUV_{max}, maximum standardised uptake value; TZ, transition zone.